

MANAJEMEN BEBERAPA FIBROID RAHIM PADA KEHAMILAN

Kadek Agus wijaya, Ni Made Youthma Dwistayani

Tabanan Regional General Hospital, Tabanan, Bali, Indonesia

Email: dyouthma@gmail.com, lotuslaundrybyheart@gmail.com

INFO ARTIKEL	ABSTRAK
Diterima 29 Oktober 2022 Direvisi 15 November 2022 Disetujui 25 November 2022	Fibroid Rahim adalah tumor jinak yang berasal dari otot polos rahim. Pada umumnya mioma uteri tidak menunjukkan gejala dan ditemukan secara kebetulan pada pemeriksaan USG kehamilan. Kami melaporkan bahwa seorang wanita 39 tahun dengan G2P1001 yang mengaku hamil 40 minggu datang dengan keluhan nyeri perut intermiten sejak pukul 04.00 pagi, yang semakin memburuk 2 jam sebelum masuk rumah sakit. Keluhan disertai keluarnya lendir darah melalui vagina. Pasien menikah 2 kali dan jarak antara anak pertama dan kedua adalah 19 tahun. Tanda-tanda vital pasien dalam batas normal. Pada pemeriksaan fisik, teraba massa dengan permukaan halus yang tampak menempel pada uterus. Pemeriksaan obstetri didapatkan: tinggi fundus uteri: 32cm, HIS+ adekuat, denyut jantung janin 140 denyut/menit, kinerja; posisi kepala. Saat dilakukan vaginal touch didapatkan adanya bukaan sebesar 1 cm dengan penipisan 25%, selaput ketuban masih utuh. Pasien didiagnosis dengan G2P10001 usia kehamilan 40-41 minggu + intra uterin hidup tunggal + primer sekunder lama + fibroid uteri. Pasien menjalani operasi caesar, hasil bayi dan ibu baik. Temuan intraoperatif ditemukan 2 mioma uteri berukuran lebih dari 5 cm yang terletak di subserosa dan intramural sehingga pasien menjalani histerektomi supravaginal. Usia pasien di atas 35 tahun merupakan salah satu pertimbangan untuk tubektomi
Kata Kunci: Kehamilan; Rahim; Supravaginal; Tubektomi	ABSTRACT <i>Uterine Fibroids is a benign tumors originating from the smooth muscle of the uterus. In general, uterine myomas are asymptomatic and are found incidentally during ultrasound examination of pregnancy. We report that a 39-year-old woman with G2P1001 who admitted she was 40 weeks pregnant came with complaints of intermittent abdominal pain since 04.00 in the morning, which was getting worse 2 hours before being admitted to the hospital. Complaints are accompanied by the discharge of blood mucus through the vagina. The patient was married 2 times and the distance between the first child and the second was 19 years. The patient's vital signs were within normal limits. On physical examination, there was a palpable mass with a smooth surface that seemed to stick to the uterus. Obstetrical examination revealed: uterine fundal height: 32cm, HIS + adequate, fetal heart rate 140 beats/minute, performance; head position. When</i>

Keywords:

Pregnancy, uterine fibroids, Supravaginal Hysterectomy, Tubectomy.

How to cite:

Wijaya, K. A., Dwistayani, N.M.Y., (2022). Manajemen Beberapa Fibroid Rahim Pada Kehamilan. *Jurnal Health Sains*, 3(11). <https://doi.org/10.46799/jhs.v3i11.645>

E-ISSN:

2722-5356

Published by:

Ridwan Institute

a vaginal touch was performed, it was found that there was an opening of 1 cm with 25% thinning, and the membranes were still intact. The patient was diagnosed with G2P10001 40-41 weeks of gestation + single alive Intra uterine + old secondary primary + uterine fibroids. The patient underwent a cesarean section, and the outcome of the baby and mother was good. Intraoperative findings found that 2 uterine myomas were measuring more than 5 cm located in the subserosa and intramural so the patient underwent a supravaginal hysterectomy. The age of the patient above 35 years is one of the considerations for tubectomy.

Introduction

Uterine Fibroids is a benign tumors originating from the smooth muscle of the uterus (Robboy et al., 2000). The prevalence of uterine myomas is 40-60% in women of childbearing age. It is said that the incidence of pregnancy with myoma is 1.2 – 10.7%.(Nurmansyah et al., 2019);(Yadav et al., 2019)

In general, uterine Fibroids are asymptomatic and are found incidentally during an ultrasound examination of pregnancy (Egbe et al., 2018). In 42% of cases, uterine fibroids can be found on physical examination if they are large (>5cm) (Lee et al., 2010).

The location, type, and size of the uterine fibroids that are suffered determine the symptoms experienced by the patient (Yoon et al., 2008). Symptoms experienced can be; Abnormal uterine bleeding which can occur in 30% of patients, and abdominal pain, if there is pressure on surrounding organs, it can cause symptoms such as polyuria, leg edema, and pelvic pain (Mise et al., 2020).

Based on the location Uterine Fibroids can be divided into three, namely submucosal, intramural, and subseros (Nurmansyah et al., 2019). Complications that may occur in pregnancy with Uterine Fibroids can be spontaneous abortion, antepartum bleeding, postpartum bleeding,

premature labor, malpresentation, and malposition (Sultana et al., 2012).

Research Methods

A 39-year-old mother with G2P1001 admitted that she was 40 weeks pregnant and came with complaints of intermittent abdominal pain since 04.00 in the morning, which was getting worse 2 hours before being admitted to the hospital. Complaints are accompanied by the discharge of blood mucus through the vagina. The patient was married twice and the distance between the first and second child was 19 years. The patient's first child was born by normal delivery. During pregnancy the patient.

Performed ANC 3 times at the obstetrics and gynecology specialist. Before this pregnancy, the patient had never complained of bleeding or abdominal pain. On general examination, the patient's general condition was good, blood pressure: 120/80 mmHg, pulse 80 times/minute, respiratory rate 20 times/minute.

The results of laboratory examinations showed hemoglobin levels of 12.1 g/dL, hematocrit 35.6%, leukocytes 8×10^3 uL, and platelets 268×10^3 uL (Nazer et al., 2022).

The patient also underwent an ultrasound examination, it was found that there was a single fetus living in the uterus

and a solid mass that looked like uterine fibroids.

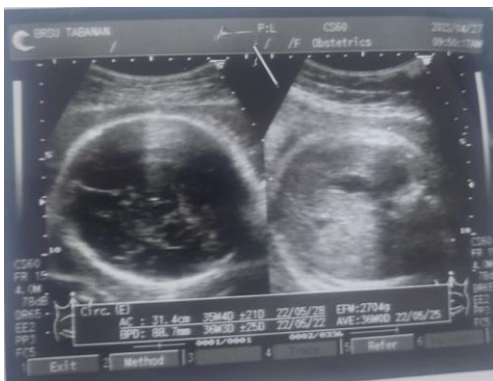

Figure 1
Ultrasound of Pregnancy

Based on the history, physical examination, and supporting examinations, the patient was diagnosed with G2P10001, 40-41 weeks of gestation + single intrauterine life + secondary old primary + uterine fibroids. Then a cesarean section was performed followed by a supravaginal hysterectomy and tubectomy.

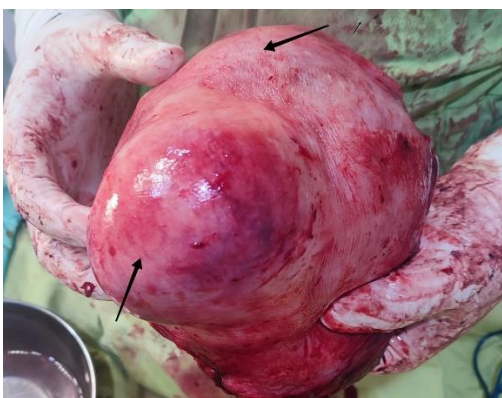


Figure 2
Post Supravaginal Hysterectomy

After the cesarean section in this patient, the baby was born women weighing 3750 grams, body length of 50 cm, and Apgar score of 8/10.

During surgery, two uterine fibroids were found, subserosa and intramural. After surgery, the patient was diagnosed to be G2P10001 40-41 weeks gestation +

single living intra uterine + primary aged secondary + multiple uterine fibroids. After surgery the patient's hemodynamic condition was stable, and the patient was discharged from the hospital after 2 days of hospitalization.

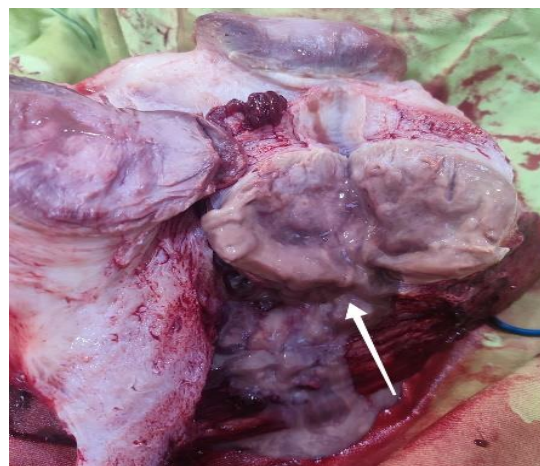


Figure 3
Intramural Uterine Fibroids with hyaline degeneration

From the results of the surgery above, another follow-up examination was carried out, namely the anatomical pathology examination. The results of anatomical pathology examination readings: benign hyperplastic smooth muscle cells that form a bundle arrangement and whorled appearance, necrosis, and mitoses do not appear.

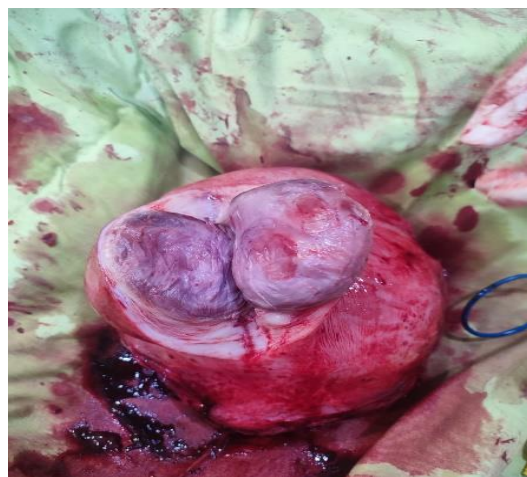


Figure 4
Subserous Uterine Myoma.

Results And Discussion

Uterine Fibroids is a benign tumors originating from the smooth muscle of the uterus. The incidence of pregnancy with Uterine Fibroids is 1: 100,000 pregnancies. The formation of Uterine Fibroids is caused by the influence of genetic, hormonal, and growth factors (Kim, 2018);(Eyong & Okon, 2020).

In 40-50% of cases of Uterine Fibroids, there are tumor-specific chromosomal irregularities that can affect extracellular matrix remodeling and estrogen-progesterone receptor status (Kim, 2018),(Eyong & Okon, 2020).

The hormones estrogen and progesterone are said to influence the growth of uterine fibroids. Uterine fibroids are often encountered during the reproductive phase and are rarely seen at the age before menarche and after menopause (Giuliani et al., 2020). Compared with normal myometrial conditions, the levels of estrogen and progesterone in Uterine Fibroids cases were found to be higher (Nurmansyah et al., 2019);(Egbe et al., 2018).

Growth factors produced by smooth muscle and fibroblasts can increase the extracellular matrix to stimulate the growth of uterine fibroids (Nurmansyah et al., 2019);(Sultana et al., 2012).

The size of uterine fibroids in pregnancy increased in 31% of cases occurring significantly before 10 weeks of gestation. The remaining 69% did not change in myoma size (Rusnaldi & Raynaldi, 2021).

Uterine fibroids that are less than 5 cm in size generally do not enlarge during pregnancy, whereas uterine fibroids larger

than 5 cm will often enlarge during pregnancy (Poovathi & Ramalingam, 2016).

The incidence of Uterine Fibroids during pregnancy is mostly asymptomatic. But pregnancy with Uterine Fibroids can worsen the pregnancy prognosis. In 10-30% of cases, Uterine Fibroids can cause complications during pregnancy, delivery, or after delivery (Sparić et al., 2017);(Ginting & Rasmaliah, 2012).

Complications experienced can be in the form of abortion, placental abruption, placenta previa, IUGR, prematurity, malpresentation, postpartum bleeding caused by uterine atony, and retained placenta (Egbe et al., 2018);(Lee et al., 2010).

Based on the location of Uterine Fibroids are divided into 3; Submucosal, intramural, and subserous uterine myomas. Uterine myomas located in the submucosa most often require intense treatment because they have severe symptomatic manifestations such as menorrhagia, metrorrhagia, dysmenorrhea, infertility, and repeated abortions (Egbe et al., 2018);(Chiaffarino et al., 2016).

In this case, the patient did not complain of symptoms that generally occur in uterine fibroids, this could be because the location of the myoma in this patient is intramural and subserosa. Both locations rarely cause symptoms unless there is pressure on surrounding organs (Nurmansyah et al., 2019).

The gap between the patient's first pregnancy and the current pregnancy is more than 10 years, so it is referred to as secondary primary. The age of patient is over 35 years ago with a high risk so the patient undergoes a tubectomy intending to prevent re-pregnancy (Nurmansyah et al., 2019).

The management of this patient was operative supravaginal hysterectomy because the myoma size was more than 5 cm and the number was more than 1. A hysterectomy was performed because of uterine atony caused by multiple uterine fibroids.

Conclusion

Uterine Fibroids is a benign tumors originating from the smooth muscle of the uterus. Uterine Fibroids often occur in women of reproductive age. Pregnant patients with Uterine Fibroids are often asymptomatic and are found incidentally during routine pregnancy examinations. Uterine Fibroids in pregnancy can worsen the prognosis of pregnancy. The complications that can occur: are abortion, placental abruption, placenta previa, IUGR, prematurity, malpresentation, postpartum bleeding caused by uterine atony, and retained placenta. Based on the location Uterine Fibroids are divided into 3, namely: submucosal, intramural, and subserosa. Uterine fibroids are the submucosal type that most often show symptoms such as menorrhagia, metrorrhagia, repeated abortions, and infertility.

BIBLIOGRAFI

- Chiaffarino, F., Ricci, E., Cipriani, S., Chiantera, V., & Parazzini, F. (2016). Cigarette smoking and risk of uterine myoma: systematic review and meta-analysis. *European Journal of Obstetrics & Gynecology and Reproductive Biology*, 197, 63–71. [Google Scholar](#)
- Egbe, T. O., Badjang, T. G., Tchounzou, R., Egbe, E.-N., & Ngowe, M. N. (2018). Uterine fibroids in pregnancy: prevalence, clinical presentation, associated factors and outcomes at the Limbe and Buea Regional Hospitals, Cameroon: a cross-sectional study. *BMC Research Notes*, 11(1), 1–6. [Google Scholar](#)
- Eyong, E., & Okon, O. A. (2020). Large Uterine Fibroids in Pregnancy with Successful Caesarean Myomectomy. *Case Reports in Obstetrics and Gynecology*, 2020. [Google Scholar](#)
- Ginting, L. Y., & Rasmaliah, J. (2012). Karakteristik penderita mioma uteri yang dirawat inap di RSUD DR. Pringadi Medan tahun 2009-2011. *Jurnal Gizi Kesehatan Reproduksi Dan Epidemiologi*, 1(1), 1–9. [Google Scholar](#)
- Giuliani, E., As-Sanie, S., & Marsh, E. E. (2020). Epidemiology and management of uterine fibroids. *International Journal of Gynecology & Obstetrics*, 149(1), 3–9. [Google Scholar](#)
- Kim, M. (2018). Spontaneous complete regression of large uterine fibroid after the second vaginal delivery: Case report. *Medicine*, 97(45). [Google Scholar](#)
- Lee, H. J., Norwitz, E. R., & Shaw, J. (2010). Contemporary management of fibroids in pregnancy. *Reviews in Obstetrics and Gynecology*, 3(1), 20. [Google Scholar](#)
- Mise, I., Anggara, A., & Harun, H. (2020). Sebuah Laporan Kasus: Mioma Uteri Usia 40 Tahun. *Jurnal Medical Profession (Medpro)*, 2(2), 135–138. [Google Scholar](#)
- Nazer, S., Andleeb, S., Ali, S., Gulzar, N., Raza, A., Khan, H., Akhtar, K., & Ahmed, M. N. (2022). Cytotoxicity, Anti-diabetic, and Hepato-protective Potential of Ajuga bracteosa-conjugated Silver Nanoparticles in Balb/c Mice. *Current Pharmaceutical Biotechnology*, 23(3), 318–336. [Google Scholar](#)
- Nurmansyah, N., Djemi, D., & Setyawati, T. (2019). Sebuah Laporan Kasus: Kista Ovarium. *Jurnal Medical Profession*, 1(3), 226–229. [Google Scholar](#)
- Poovathi, M., & Ramalingam, R. (2016). Maternal and Fetal Outcome in Pregnancy with Fibroids: A Prospective Study. *International Journal of Scientific Study*, 3(11), 169–172. [Google Scholar](#)
- Robboy, S. J., Bentley, R. C., Butnor, K., & Anderson, M. C. (2000). Pathology and pathophysiology of uterine smooth-muscle tumors. *Environmental Health Perspectives*, 779–784. [Google Scholar](#)
- Rusnaldi, R., & Raynaldi, J. (2021). Seksio Sesarea dan Miomektomi pada Kehamilan dengan Mioma Uteri: Laporan Kasus. *Jurnal Kedokteran Nanggroe Medika*, 4(2), 11–18. [Google Scholar](#)
- Sparić, R., Kadija, S., Stefanović, A., Spremović Radjenović, S., Likić Ladjević, I., Popović, J., & Tinelli, A.

(2017). Cesarean myomectomy in modern obstetrics: More light and fewer shadows. *Journal of Obstetrics and Gynaecology Research*, 43(5), 798–804. [Google Scholar](#)

Sultana, R., Noor, S., Nazar, A. F., Abbasi, N., Bashir, R., Khan, B., & Saleem, F. (2012). Safety of caesarean myomectomy. *Journal of Ayub Medical College Abbottabad*, 24(2), 120–121. [Google Scholar](#)

Yadav, R., Rani, K., & Najam, R. (2021). *Maternal and fetal outcomes in pregnancies complicated with intrahepatic cholestasis of pregnancy*. [Google Scholar](#)

Yoon, S.-W., Lee, C., Cha, S. H., Yu, J.-S., Na, Y.-J., Kim, K. A., Jung, S.-G., & Kim, S.-J. (2008). Patient selection guidelines in MR-guided focused ultrasound surgery of uterine fibroids: a pictorial guide to relevant findings in screening pelvic MRI. *European Radiology*, 18(12), 2997–3006. [Google Scholar](#)

Copyright holder :

Kadek Agus wijaya, Ni Made Youthma Dwistayani
(2022)

First publication right :

[Jurnal Health Sains](#)

This article is licensed under:

