

CONDILOMATA LATA AS CLINICAL MANIFESTATION OF SECONDARY SYPHILLIS IN PREGNANCY: STUDY CASE REPORT

A A Ayu Adisti Nina Yuniandari, Diana Wijayanti

Muhammadiyah Hospital, Bandung, West Java, Indonesia

Email: agungayunina@gmail.com, adisti.nina@gmail.com

ARTIKEL INFO

ABSTRACT

Date received:

02 August 2022

Revision date:

10 September 2022

Received date:

25 September 2022

Keywords:

secondary syphilis;

pregnancy;

condyloma lata

Syphilis is one of the most common sexually transmitted infection caused by *Treponema pallidum*. Syphilis is called the “great imitator” as it can present very similar to a large variety of other diseases, which can sometimes complicate its diagnosis, especially in the later stages. One of the symptoms of secondary syphilis is condyloma lata. This report aims to discuss the case report information related condyloma lata as clinical manifestation of secondary syphilis in pregnancy. We describe case G1P0A0, a 29-year-old woman who is 28 weeks pregnant. The patient's main complaint upon arrival was that he had been developing larger and more frequent warts on his genitalia for the past month. Multiple 2 cm grey circular plaques with a localized status were found on the labia majora. A VDRL serological examination was performed as a follow-up examination on June 16; the results were reactive. At 28 weeks of gestation, the patient was diagnosed with secondary syphilis in the form of condyloma lata based on the history, physical examination, and supportive examination. Erythromycin 500 mg 4x1, paracetamol 500 mg for pain, and a 0.9% NaCl compress were administered to the patient as treatment. Reevaluated after the first month. The VDRL test yielded a titer of 1: 16 and the complaints of lumps in the genitalia had vanished. This report is using the literature review technique from PUBMED with PICO format. We use the specific question about condyloma lata treatment in secondary syphilis disease. Based on inclusion and exclusion criteria there are two research articles that appropriate with this case. Condyloma lata is one manifestation of secondary syphilis caused by *Treponema pallidum*. The diagnosis of condyloma lata in this case was established based on anamnesis, physical examination, and serologic findings. Treatment with Erythromycin gave satisfactory result. Serologic examination as follow up needs to be performed at 6 and 12-months after the initial treatment to monitor the success of therapy.

Introduction

Treponema pallidum is the bacteria that causes the sexually transmitted illness syphilis (Majid, 2010). Syphilis is widespread throughout the world and is a serious issue in

developing nations. According to age, those between the ages of 20 and 30 are most commonly affected with syphilis. Untreated early syphilis will result in transmission to the

How to cite:

Yuniandari, A. A. N. Y. Wijayanti. D. (2022). Condilomata Lata as Clinical Manifestation of Secondary Syphilis in Pregnancy: Study Case Report. *Jurnal Health Sains* 3 (9)

<https://doi.org/10.46799/jhs.v3i9.592>

E-ISSN:

2723-6927

Published by:

Ridwan Institute

fetus in 40% of pregnant women. The prevalence of syphilis is currently rising, making it a health issue. According to information from the Global AIDS Response Progress Reporting (GARPR), there may be five million cases of syphilis among people aged 15 to 49 reaching up to 55,000 cases annually (Newman, 2015). In 2017, there were 30,644 primary and secondary syphilis cases. Since 2013, this number has climbed by 76%. The epidemic of primary and secondary syphilis as well as the rising rate of screening for STDs are to blame for this rise in syphilis prevalence. In women, the frequency of syphilis increased by 30.4% between 2017 and 2018.

Congenital syphilis can be contracted from the mother at birth, but most instances are brought on by intrauterine infection. Congenital syphilis risk is inversely correlated with the mother's syphilis stage at conception. Congenital syphilitic lesions often develop 4 months into pregnancy, by which time the fetus is immune competent. *Treponema pallidum* can be found in the placenta, umbilical cord, and amniotic fluid due to the fact that intrauterine infection is transplacental. Because of the important conditions of pregnant patient with syphilis disease, through this report we try to discuss the case report information related condyloma lata as clinical manifestation of secondary syphilis in pregnancy.

Multiple phases of syphilis exist. Primary syphilis, secondary syphilis, latent syphilis, and tertiary syphilis are the four phases of syphilis, respectively. There are many different clinical manifestations of secondary syphilis, such as rash, lymphadenopathy, and mucocutaneous lesions like condyloma lata and mucous patches. A secondary syphilis known as condyloma lata manifests as grayish-white

papules in warm, humid environments. Condyloma lata is diagnosed based on the history and physical examination. The lump in the wet area is the main complaint. During a physical examination, hypertrophic, granulomatous red-brown tissue was discovered to be lesions with efflorescence. Surface that is smooth, elevated, or cauliflower-shaped, as well as lesions that have treponemes. The following describes a case of condyloma lata in a woman who was 28 weeks pregnant G1P0A.

Study Case The patient is a 29 years old woman who is 28 weeks along with her first pregnancy. On June 16, 2022, the patient was admitted to the hospital with the primary complaint that she had genital warts that had appeared a month earlier and were escalating in size. The wart's surface seems smooth and wet to the touch. The outer genitalia is where the warts are located. The patient had never before gone through this. The patient, who has only ever been married once, denies ever having had intercourse with anyone other than her husband. The final sex took place in April 2022. The patient's husband, who was genetically carried out, did not use condoms during sexual activity. The patient's husband allegedly had sex with prostitutes without wearing a condom in 2021 and admitted to having previously experienced genital injuries in November of that same year but choosing not to seek medical attention. The patient was not currently on long-term steroids, had no history of weight loss in the previous six months, or any genital disorders. It is known that the patient has a history of penicillin allergy. Her vital signs and overall status were within normal ranges, and she appeared to be in good health. Multiple gray plaques averaging 2 cm in diameter, with a circular shape, and being localized on the labia majora.

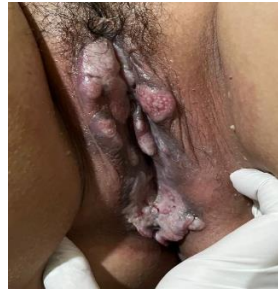

Figure 1
On the labia majora, there are several whitish plaques that are 2 cm in diameter and spherical in shape

On June 16, a VDRL serological examination was performed as a follow-up examination; the outcomes were reactive (Emerson CR, 2009). At 28 weeks of gestation, the patient was diagnosed with secondary syphilis in the form of condyloma lata based on the history, physical examination, and supportive examination. Erythromycin 500 mg four times a day, paracetamol 500 mg for pain, and 0.9% NACL compresses were used as treatment for the patients. Re-examined after a month. When complaints of genital lumps vanished, a follow-up examination was

conducted, and the results revealed a titer of 1:8 for the VDRL test. Patients are encouraged to have the exam repeated in three, six, and twelve months.

Method

Using the PICO format with the questions about how to treat condyloma lata.

With inclusion criteria:

1. Appropriate with keywords
2. Published at the last of 10 years
3. Full paper accessed

Exclusion criteria:

1. Article review type

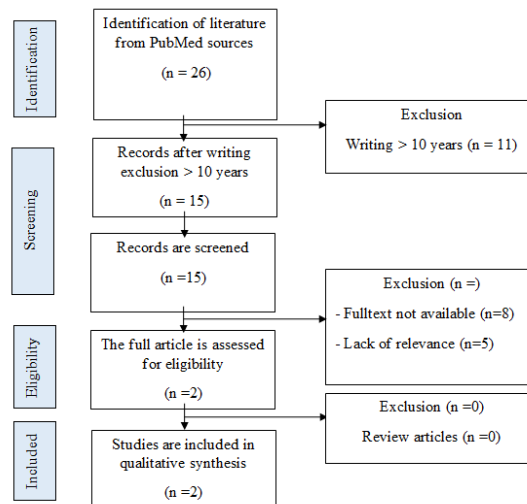


Figure 2
Search terms and publication selection process (PRISMA Flowchart)

Table 1
Charting Data

Result	Population/Patient /Problem	Intervention/ Indicator	Index/ Compar	ator	Results
Journal Writer					

1	Pourang et al., 2021	Nine patients with secondary syphilis diagnosed and presented with condyloma lata. Patient age range was 22-50 years. All of 9 patients presented with hypertrophic anogenital lesions.	Seven from nine patients were treated with intramuscular dose of Penicillin G Benzathine (2.4 million units). Meanwhile, the remaining patients were treated with intravenous Penicillin G.	-	Follow up and monitoring of rapid plasma regain titers. This report showed unknown result because of no one patient visit the doctor after the treatment period.
2	Bjekic and Vlajinac, 2019	25 years old woman with manifestation of secondary syphilis and presented condyloma lata on her vulva.	The patient received a single dose of 2.4 million units of intramuscular Benxathine Penicillin G as a treatment procedure.	-	The lesions completely improved three weeks after treatment procedure. Additionally, six months later, the Venereal Disease Research Laboratory titer significantly decrease (1:4).

Discussion

Syphilis can be found during pregnancy, which is one way to stop congenital syphilis from occurring. The primary step in preventing congenital syphilis is identifying and treating pregnant women who are infected with the disease, as penicillin treatment for syphilis during pregnancy can prevent congenital infection by up to 98%. Serological tests (VDRL and TPHA) should be conducted throughout prenatal care, including at the initial visit, again at 28 weeks of pregnancy, and at birth for high-risk individuals (Goh BT, 2005)

Early and late stages of the syphilis clinical course are distinguished. Early syphilis, which includes primary syphilis, secondary syphilis, and early latent syphilis, develops within a year of the main infection. The trinity of neurosyphilis, cardiovascular syphilis, and late benign syphilis, also known as gummatous syphilis, is included in late

latent syphilis, which develops more than a year after the initial lesion first appears. 3–12 weeks after the first primary syphilis lesions appear, secondary syphilis sets in. Secondary syphilis is frequently referred to as the great imitator because to the abnormalities that subsequently develop and have a picture that can resemble a range of other diseases (Rocha Felix, 2015). A clinical sign of secondary syphilis is condyloma lata, which appears as grayish white lesions in hot, humid climates occurs as a result of skin damage in the body's moist places. Flat plaques that are pale, confluent in shape, and have erosion on their surface are the clinical Signs of condyloma lata (Timmons, 2018) The labia majora is one area where condyloma lata frequently develops. Armpits, the space between the fingers, and the region under the breast folds are examples of perianal and fold regions (Fitzpatrick TB, 2008) T. pallidum bacteria

are present in enormous concentrations and are extremely contagious in these lesions. In secondary syphilis, lesions can arise before or

right after the widespread lesions (Minarto, 2014).



Figure 3

Results of physical examination after one month It was found that the lump in the genitals had disappeared.

The patient's main complaint in this instance was that she had many gray-colored tumors on her genitals. On the labia majora, the lesion's surface appears bright and wet (Bjekic M, 2019) In condyloma lata, these clinical signs and symptoms are pathognomonic (Deshpande DJ, 2009) Since the patient was unaware of the earlier vaginal sores, it's possible that the patient had an ulcer in the early stages of the disease but was unaware of it because syphilis ulcers don't hurt. In this instance, the patient's husband, who had previously engaged in sexual activity with a prostitute, was the source of the patient's syphilis infection. Three primary factors—history, physical examination, and corroborating research—can be used to diagnose syphilis (Ghanem KG, 2011) Dark-field microscopy, the gold standard for the diagnosis of syphilis, is used to identify pathogens. Serological testing is currently the predominant method of syphilis diagnosis. Syphilis can be detected using this test at any stage (World Health Organization, 2015).

Serological tests can be broadly divided into two categories: treponemal and nontreponemal tests. Rapid Plasma Reagent (RPR) and VDRL nontreponemal examinations were employed for screening and follow-up care. The sensitivity and specificity of VDRL are 86% and 85%,

respectively, while those of RPR are 78% and 85% (Wiwanitkit V, 2009). The patient will have reactive results 4-5 weeks following the infection. A high titer is a sign that the infection is active (E Lyytikäinen, 2008) FTA-ABS, TPPA, and TPHA are the components of the treponemal examination. These three tests, which have higher sensitivity and specificity, namely >95% and >99%, aid to confirm the diagnosis (AAAAN Yuniandari, 2015).

In this instance, secondary syphilis was discovered in the patient during 28 weeks' gestation (third trimester) (K Adachi, 2018). Syphilis screening was conducted on the patient at 28 weeks' gestation, but it wasn't done at the initial appointment, delaying the diagnosis. For the first three months, follow-up clinical exams and non-treponemal serological tests were conducted monthly; they were then repeated at 6, 12, and 24 months (Rocha Felix, 2015) If the nontreponemal examination titer has decreased by four times by the sixth or twelfth month, the treatment is considered to have been successful (Workowski 2015). Unresponsive or 4-fold-increasing titers indicate either treatment failure or reinfection. The most effective treatment for syphilis in pregnant women is penicillin. There haven't been any substantial T. pallidum penicillin-resistant strains discovered as of now (Rac MW, 2017). Penicillin therapy is used to treat maternal illness, stop the spread of it to the fetus, and cure syphilis that has already affected the fetus in pregnant women. One of the alternatives for treating primary and secondary syphilis, including condyloma lata in pregnant women, especially those who are penicillin allergic, is erythromycin (Ling J, 2015) Because the patient had a history of penicillin allergies, erythromycin 500 mg four times a day for a month was prescribed to them (Kemenkes 2013). Clinical symptoms improved and the VDRL and TPHA titers dropped after a month of follow-up, showing that the patient had responded to the treatment. lesions are known as condyloma lata. Syphilis is diagnosed based on a patient's medical history, physical examination, and investigations. Based on (Nova Scotia, 2020). Communicable Diseases Manual, the preferred treatment for pregnant women with primary, secondary, and early latent syphilis is Benzathine Penicillin G 2.4 million units weekly for 1 – 2 doses (Baughn, 2005). Several experts recommended other regimen with 3 weekly

doses of Benzathine Penicillin G in HIV infected individuals (Pourang, 2021).

Conclusion

Condyloma lata is one manifestation of secondary syphilis caused by *Treponema pallidum*. The diagnosis of condyloma lata in this case was established based on anamnesis, physical examination, and serologic findings. Pregnant women diagnosed with syphilis should be treated immediately. Syphilis is easily treated using the antibiotic penicillin. Primary, secondary and latent syphilis can all be treated with penicillin, but it is most effective in the primary and secondary phases. Treatment with Erythromycin gave satisfactory result. Serologic examination as follow up needs to be performed at 6 and 12-months after the initial treatment to monitor the success of therapy.

Bibliography

- Majid N, Bollen L, Morineau G, Daily SF, Mustikawati DE, Agus N, et al. 2010. Syphilis among female sex workers in Indonesia: Need and opportunity for intervention. *Sex Transm Infect.* 86(5). [Google Scholar](#)
- Newman L, Rowley J, Hoorn S Vander, Wijesooriya NS, Unemo M, Low N, et al. 2015. Global Estimates of the Prevalence and Incidence of Four Curable Sexually Transmitted Infections in 2012 Based on Systematic Review and Global Reporting. Vol. 10, *PLoS ONE.* [Google Scholar](#)
- AAAAN Yuniandari, World Health Organization. 2015. Kajian Nasional Respon HIV di Bidang Kesehatan Republik Indonesia. In: *Acta Universitatis Agriculturae et Silviculturae Mendelianae Brunensis.* [Google Scholar](#)
- K Adachi, Prevention C for DC and STDs in Women and Infants - 2018 Sexually Transmitted Diseases Surveillance. 2018.

Condilomata Lata as Clinical Manifestation of Secondary Syphilis in Pregnancy: Study Case Report

- STDs in Women and Infants. [Google Scholar](#)
- Goh BT. 2005. Syphilis in adults. *Sex Transm Infect.* 81(6). [Google Scholar](#)
- Emerson CR. 2009. Syphilis: A review of the diagnosis and treatment. *Open Infect Dis J.* 3(SPEC.ISS.1). [Google Scholar](#)
- Ghanem KG, Workowski KA. 2011. Management of adult syphilis. Vol. 53, *Clinical Infectious Diseases.* [Google Scholar](#)
- Deshpande DJ, Nayak CS, Mishra SN, Dhurat RS. 2009. Verrucous condyloma lata mimicking condyloma acuminata: An unusual presentation. *Indian J Sex Transm Dis.* 30(2). [Google Scholar](#)
- Minarto H. 2014. Condyloma Lata In A 21-Year-Old Male Treated With Doxycycline: A Case Report. *J Biomedik.* 6(2). [Google Scholar](#)
- Pourang A, Fung MA, Tartar D, Brassard A. 2021. Condyloma lata in secondary syphilis. *JAAD Case Reports.* 10. [Google Scholar](#)
- Fitzpatrick TB, Wolff K, Goldsmith LA, Katz SI, Gilchrest BA, Paller AS, et al. 2008. Fitzpatrick's dermatology in general medicine [electronic resource]. McGrawHills AccessMedicine Clinical library. [Google Scholar](#)
- E Lyytikäinen, Atlas of Sexually Transmitted Diseases. 2008. Atlas of Sexually Transmitted Diseases. [Google Scholar](#)
- Rocha Felix, Silva, Bordalo C, Pinto, Pereira Bandeira De Mello MDB, Toscano De Brito JR, et al. 2015. Successful treatment of pregnant women with syphilis and penicillin allergy. *World Allergy Organ J.* 8. [Google Scholar](#)
- Rac MWF, Revell PA, Eppes CS. 2017. Syphilis during pregnancy: a preventable threat to maternal-fetal health. Vol. 216, *American Journal of Obstetrics and Gynecology.* [Google Scholar](#)
- Baughn RE, Musher DM. 2005. Secondary syphilitic lesions. Vol. 18, *Clinical Microbiology Reviews.* [Google Scholar](#)
- Wiwanitkit V. A. 2009. cost-utility analysis of Treponema pallidum haemagglutination (TPHA) testing for syphilis screening of blood donors: Is the TPHA test useful for syphilis screening in a blood centre? Vol. 7, *Blood Transfusion.* [Google Scholar](#)
- Workowski KA, Bolan GA. 2015. Sexually transmitted diseases treatment guidelines, 2015. *MMWR Recomm Reports.* 64(3). [Google Scholar](#)
- Ling J, Gu F, Mei J, Xu Y, Lu M, Jiang M, et al. 2015. The epidemiological characteristics of maternal syphilis and neonatal outcomes with intervention in Jiangyin from 2014 to 2015. *Clin Exp Obstet Gynecol.* 45(3). [Google Scholar](#)
- Timmons P, Gada R. 2018. Syphilis in pregnancy. Vol. 30, *Obstetrics, Gynaecology and Reproductive Medicine.* 2020. [Google Scholar](#)
- Kemeterian Kesehatan RI. 2013. Pedoman Tata Laksana Sifilis Untuk Pengendalian Sifilis Di Layanan Kesehatan Dasar. Direktorat Jenderal Pengendalian Penyakit dan Penyehatan Lingkungan. [Google Scholar](#)
- Bjekic M, Vlajinac H. 2019. Condylomata Lata on the Vulva. *JSM Obstet Gynecol* 5: 2. [Google Scholar](#)
- Nova Scotia, Communicable Diseases Manual. 2020. Syphilis. Nova Scotia Press. Scotlandia. [Google Scholar](#)

Copyright holder:

A A Ayu Adisti Nina Yuniandari, Diana Wijayanti (2022)

First publication right:

Jurnal Health Sains

This article is licensed under:

